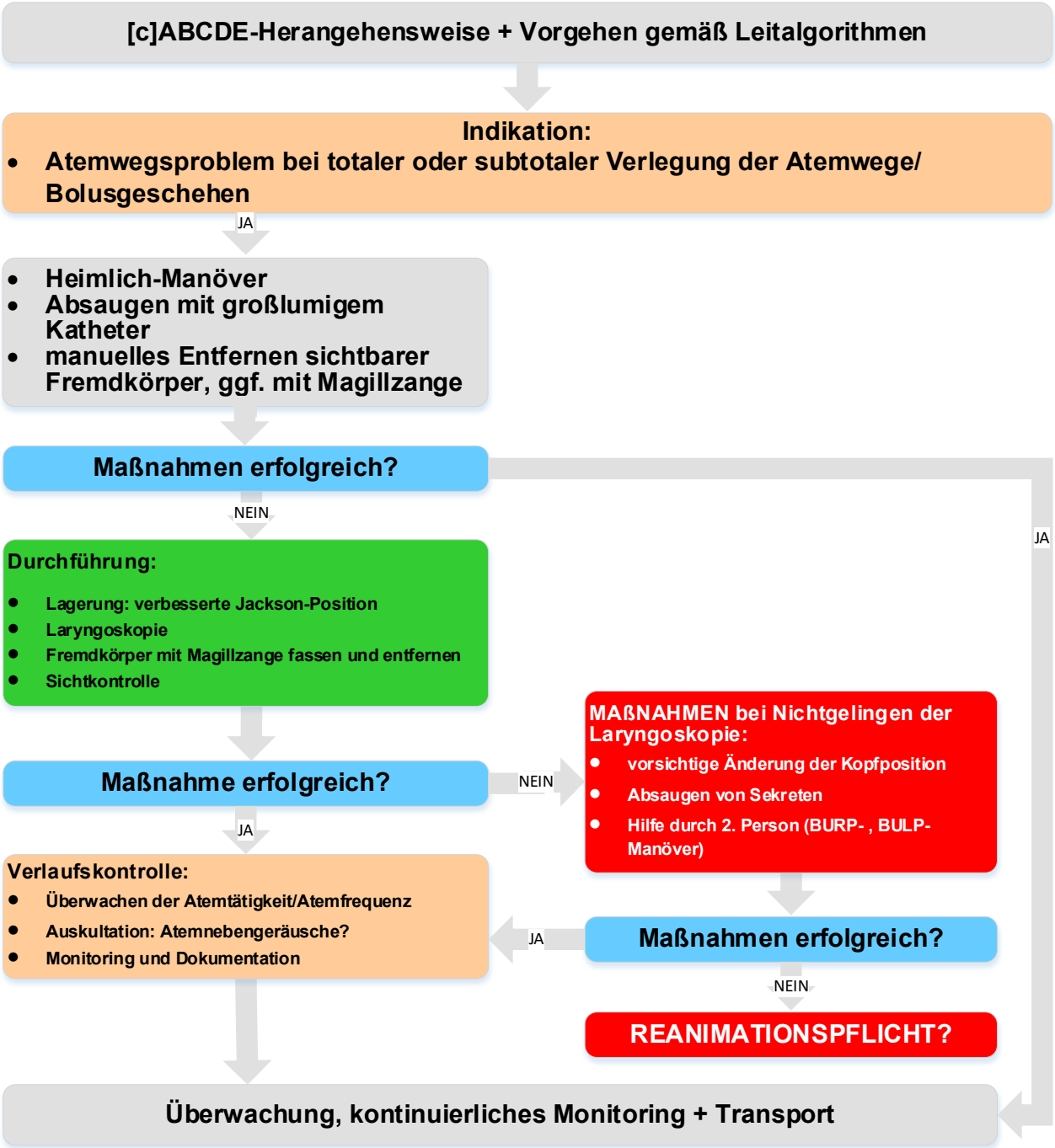(VIDEO-) LARYNGOSKOPIE – FREMDKÖRPERENTFERNUNG MAGILL-ZANGE